

Chilaiditi Syndrome: A Case Presented with Peritonitis Symptoms

Mohammad Esmail Hejazi¹, Fatemeh Seifar²✉, Hanieh Mohammadpour³, Farzad Salmanezhad Khorami⁴, Leila Namvar³, Yasin Hejazi², Farid Hajibonabi²

¹Associate professor in Respiratory Diseases, Tuberculosis and Lung Disease Research Center, Tabriz University of Medical Sciences, Tabriz, Iran

²Medical Student, Student Research Committee, Faculty of medicine, Tabriz University of Medical Sciences, Tabriz, Iran

³Doctor of Internal Medicine, Tuberculosis and Lung Disease Research Center, Tabriz University of Medical Sciences, Tabriz, Iran

⁴Resident of Emergency Medicine, Tabriz University of Medical Sciences, Tabriz, Iran

✉ Corresponding author's E-mail: f.seifar@gmail.com

ABSTRACT: We reported a patient affected by the Chilaiditi's syndrome, the interposition of the small or large intestine between liver and right hemi diaphragm which is a rare asymptomatic condition. A 70-year-old female with a history of respiratory failure was presented with abdominal pain characteristic for peritonitis. The radiologic findings and symptoms resolved after conservative management with bowel rest and decompression. In conclusion, conservative treatment in addition to radiologic findings were representative of Chilaiditi syndrome.

Keywords: Chilaiditi syndrome, Abdomen, Chilaiditi sign

ORIGINAL ARTICLE
PII: S2322-47891700008-7
Received 15 Nov. 2017
Accepted 15 Dec. 2017

INTRODUCTION

Chilaiditi syndrome is a temporary or permanent interposition of the colon between the liver and right hemidiaphragm. The incidence of this syndrome is rare and seems to increase with aging, chronic respiratory disease, abnormal colonic motility and chronic constipation (Danve and Kulkarni, 2015; Ivan, 1978). The asymptomatic radiologic presentation is called chilaiditi sign. Chilaiditi sign is incidentally reported in 0.025%–0.28% of chest radiographs and 1.18%–2.4% of abdominal Computed Tomography (CT) scans (Fuessl, 2014; Indiran et al., 2017). Symptoms due to Chilaiditi syndrome include distention, abdominal pain, bloating, nausea, emesis and constipation (Gurvits et al., 2009)

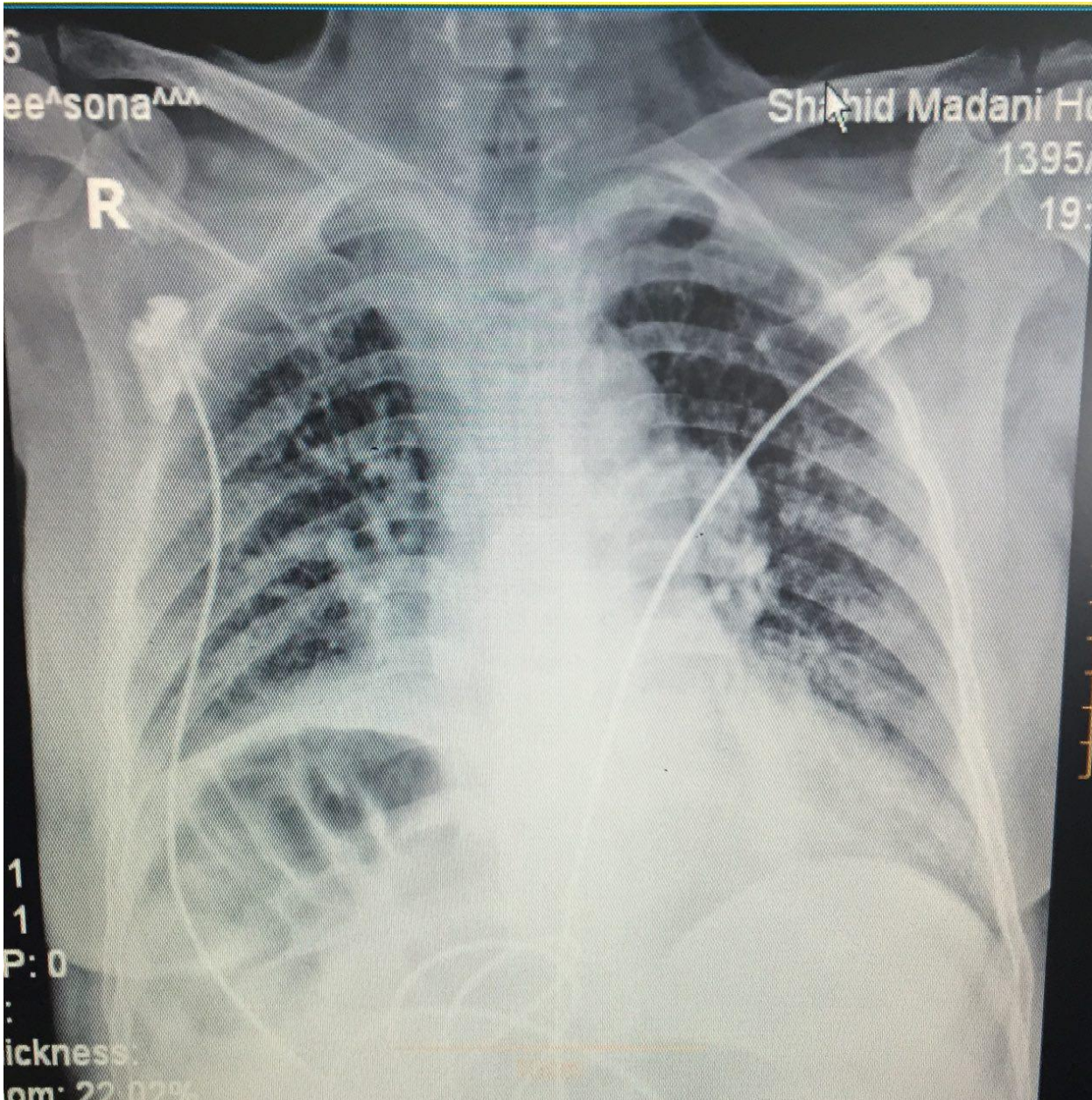
CASE PRESENTATION

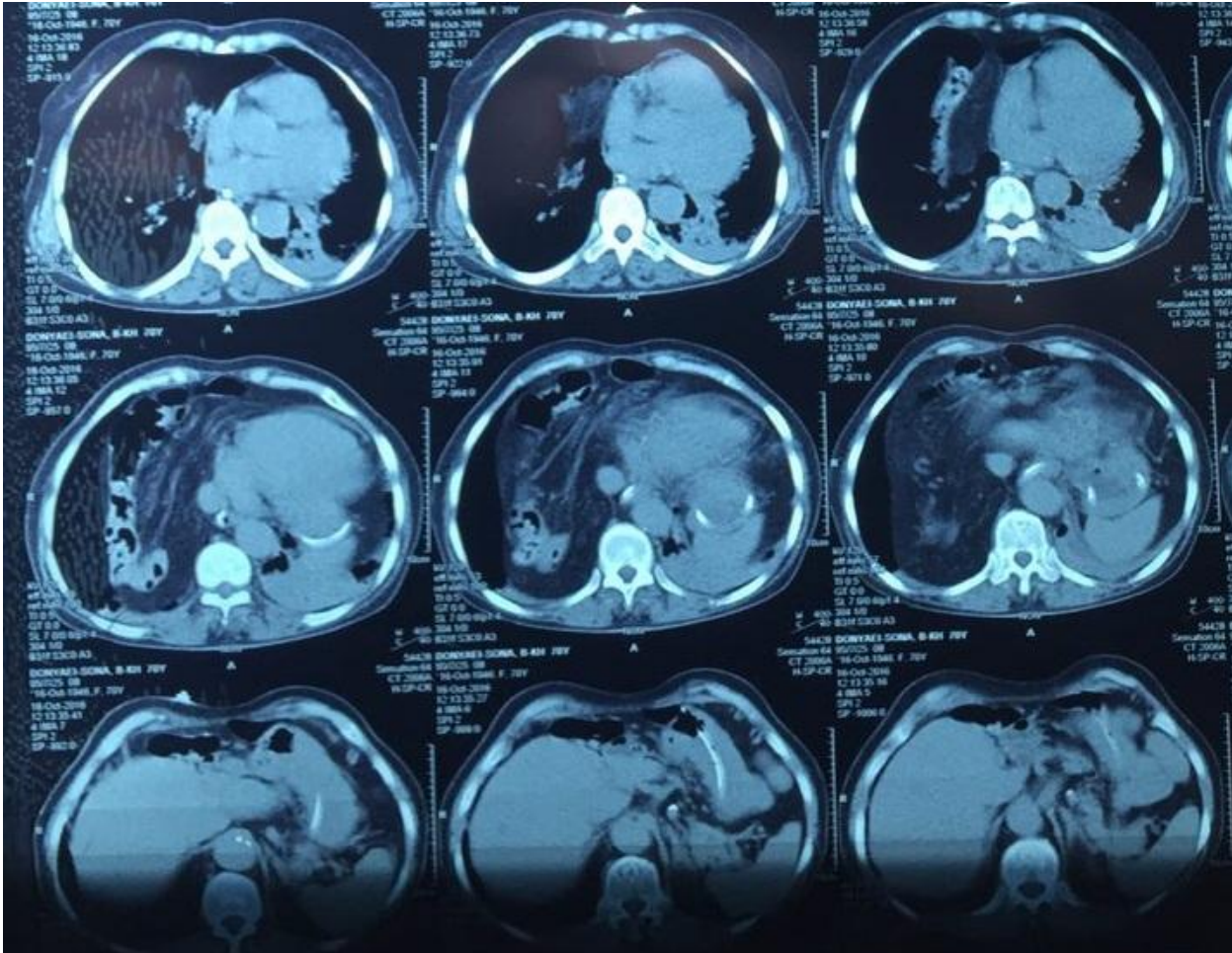
A 70-year-old woman was admitted to the Intensive Care Unit (ICU) with a history of gradually chest pain localized to the retrosternal region without radiation. At the

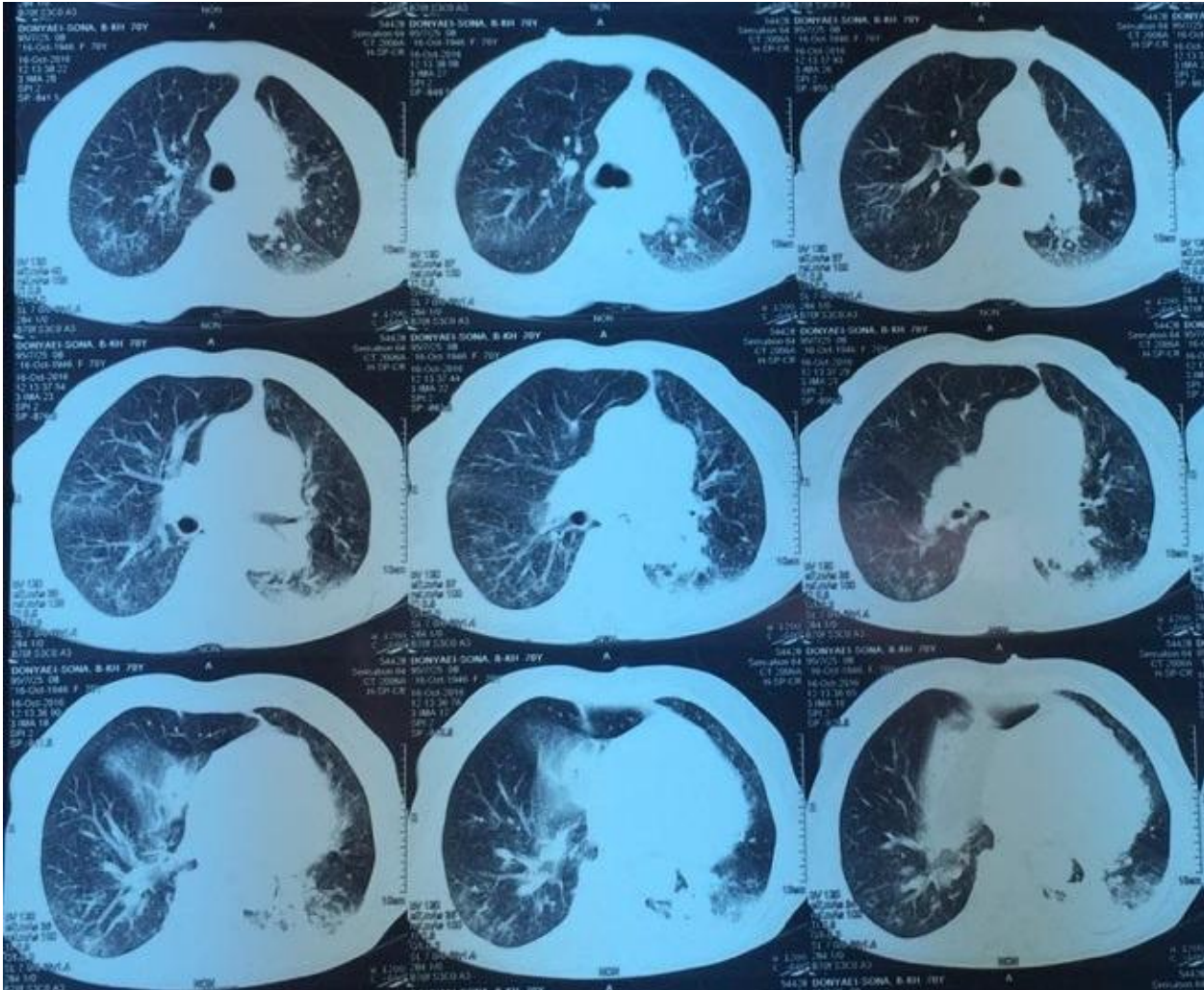
time of admission, she underwent orotracheal intubation because of respiratory failure. She underwent treatment approach in ICU and was extubated based on the relief of respiratory condition and Blood gas analysis. After extubation, she presented an abdominal pain. Her pain was associated with intermittent nausea, constipation, without emesis or obstipation. She didn't have the similar pain before the admission to hospital. On physical examination, her hemodynamic state was stable. Patient was afebrile with normal vital signs. Her abdominal examination showed a distended bowel with tenderness especially localized in right upper quadrant, and decreased bowel signs. The Murphy sign was negative as well as the rebound tenderness in all four abdominal quadrants. Laboratory results of the complete blood count, amylase and lipase, urinalysis and liver function tests were normal. The Electrocardiogram (ECG) didn't show a specific change. On imaging studies, the ultrasonography demonstrated unremarkable reports. Chest X-ray (CXR) was performed, which revealed pneumoperitoneum, the

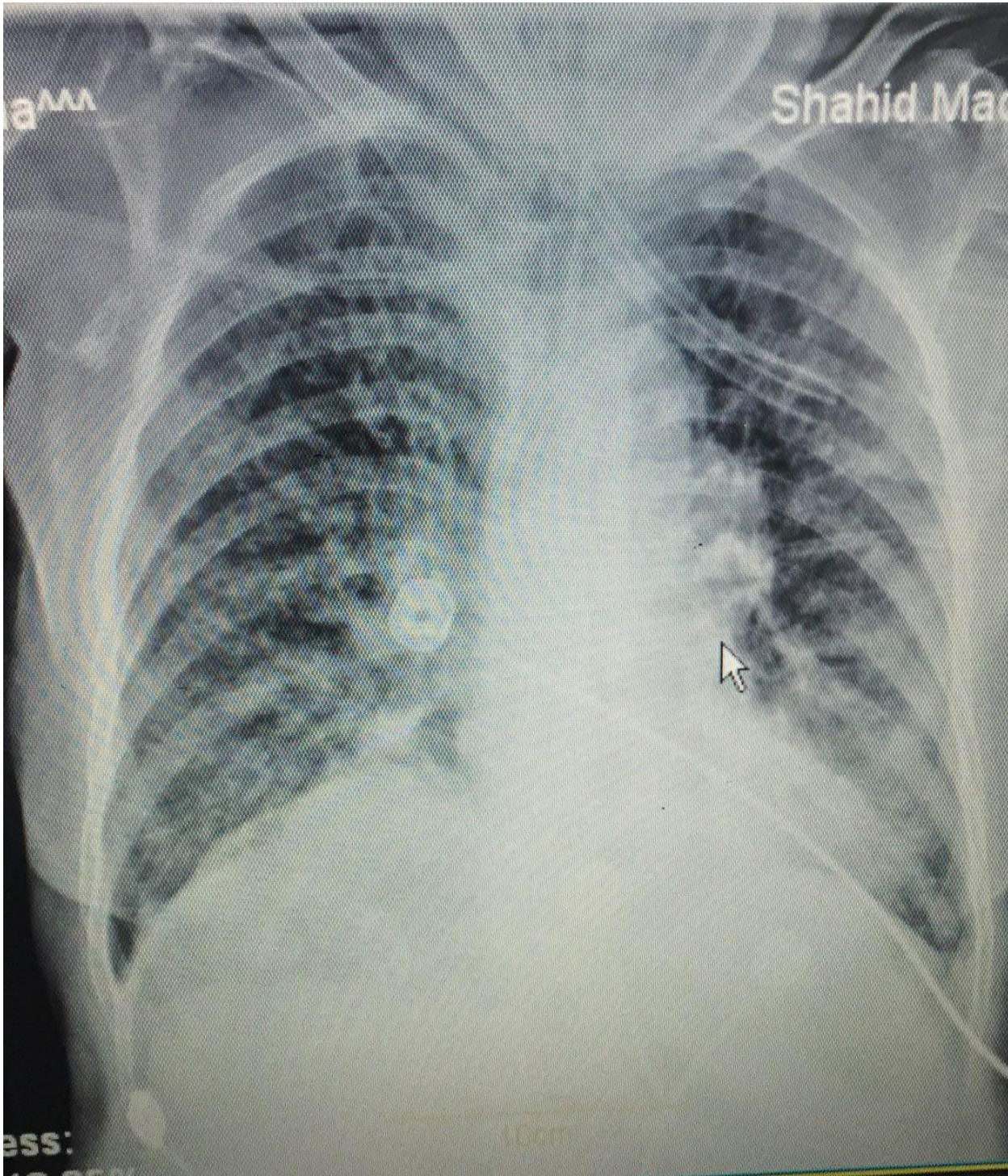
accumulation of air beneath the right hemi-diaphragm (figure 1). The chest and abdominal CT scans were performed with intravenous and oral contrast which revealed interposition of bowel loops into Morison pouch. The CT scans also demonstrated thickening of the small intestine walls with inflammatory changes (figure 2 and 3). Based on the patient's presentation and imaging results, the surgery consultation was taken. She was candidate for open surgery with the diagnosis of peritonitis. She underwent preoperative fasting as well as nasogastric tube and Foley catheter insertion. In the meantime, patient had defecation

and the symptoms resolved in 12 hours. The second CXR was set after 24 hours, which demonstrated normal imaging findings (figure 4). In light of the radiographic findings, and patient's symptoms, the diagnosis of Chilaiditi syndrome was made. She had two other episodes of similar abdominal pain, which was managed conservatively with a stool softeners and analgesics. She presented with complete resolution of abdominal pain with improved regularity of bowel movements after the treatment.









DISCUSSION

Chilaiditi syndrome was first described in 1910, as an interposition of the intestinal loops between liver and right hemi diaphragm (Yagnik, 2010). The word Chilaiditi sign, is the radiologic description of this condition which can be

misinterpreted as pneumoperitoneum (Ebata et al., 1965; Indiran et al., 2017). The bowel loops are more predisposed to interpose in Morison pouch. The transverse colon and colonic hepatic flexure as well as small bowel are susceptible to be entrapped between diaphragm and liver (Ansari and Lay, 2011; Gurvits et al., 2009). The

etiologic basis of this condition is still unclear but a few risk factors are known to predispose patients to develop Chilaiditi syndrome. These factors include reduced liver dimensions, redundancy of the colon, congenital hepatic, agenesis of the mesentery suspensory ligaments, intestinal or diaphragmatic anomalies (right hepatic lobe segmental agenesis) chronic constipation, redundant and hypermobile transverse mesentery and transverse colon, and severe chronic obstructive pulmonary disease (Platz et al., 2006; Suarez-Grau et al., 2011). The patient may present with signs and symptoms of bowel obstruction, such as abdominal pain, nausea, emesis, anorexia, distension, and obstipation. Our patient was also presented with these symptoms together with tenderness in right upper quadrant (Baumer, 1988). The diagnosis of Chilaiditi's syndrome may be challenging due to symptoms and radiologic findings of pneumoperitoneum. The should be considered based upon imaging (radiographic) confirmation of the abnormal inter positioning of the colon and the occurrence of associated symptoms in a patient with abdominal and/or respiratory symptoms (Moaven and Hodin, 2012; Yin et al., 2012). For treatment, it's important to rule out the more serious condition of pneumoperitoneum and consider Chilaiditi syndrome, where misdiagnosis of acute abdomen might result in unnecessary surgical intervention. The therapeutic approach in Chilaiditi syndrome includes bowel rest, aggressive fluid rehydration, bowel decompression, laxatives and enemas. Repeating the chest radiography after bowel decompression can demonstrate the fading of sub diaphragmatic air (Ansari and Lay, 2011; Mateo de Acosta Andino et al., 2012). These symptoms may similarly repeat in the patient with Chilaiditi syndrome. our patient had two episodes of abdominal pain with the presentation mimicking the peritonitis. Conservative treatment with repeat radiology resulted in pain relief and disappearance of the air below the diaphragm.

CONCLUSION

To sum up, this case presentation reports the Chilaiditi syndrome as a complication of respiratory failure initiated with symptoms misleading to acute abdomen. This condition usually resolves with conservative management in patients with predisposing factors to the development of Chilaiditi syndrome as well as radiographic Chilaiditi sign.

Competing interests

The authors have stated explicitly that there are no conflicts of interest in connection with this article.

Acknowledgments We appreciate our study participant, who helped us to work on this report.

Authors' contribution

MEH was the clinical supervisor and designed the study. FS and HM collected the data. FSK, FH and YH made contribution between data and patient's document. The first draft of manuscript was prepared by FS and LN which was reviewed by the rest of authors. The revision was made by FS, FH and FSK under the supervision of MEH. The final version of the manuscript was read and accepted by all the authors.

REFERENCES

- Ansari H and Lay J. (2011). Chilaiditi syndrome and associated caecal volvulus. ANZ Journal of Surgery, Case Reports, Letter, Australia.
- Baumer F, Weber P and Horl M (1988). The Chilaiditi syndrome as a cause of acute abdomen. Zentralblatt für Chirurgie, 113(21), 1415–1418. .
- Danve A and Kulkarni S (2015). Beware of Chilaiditi sign. Journal of Community Hospital Internal Medicine Perspectives, 5(5), 28622.
- Ebata K, Yamashita H and Yokoyama S (1965). X-ray of Chilaiditi syndrome. Rinsho hoshasen. Clinical radiography, 10(8), 607–613.
- Gurvits G, Lau N, Gualtieri N and Robilotti J (2009). Air under the right diaphragm: colonoscopy in the setting of Chilaiditi syndrome. Gastrointestinal Endoscopy, 69(3Pt2), 758–9; discussion 759. <https://doi.org/10.1016/j.gie.2008.12.238>
- Indiran V, Kannan K, Ramachandra Prasad T and Maduraimuthu P (2017). Chilaiditi sign. Abdominal Radiology, 42(8), 2188–2189. <https://doi.org/10.1007/s00261-017-1104-9>
- Ivan, D (1978). Chilaiditi syndrome. Orvosi hetilap, 119(21), 1299–1300.
- Mateo de Acosta Andino D, Aberle, C , Ragauskaitė L, Khair G, Streicher A, Bartholomew J and Kacey D (2012). Chilaiditi syndrome complicated by a closed-loop small bowel obstruction. Gastroenterology & Hepatology, 8(4), 274–276.
- Moaven O and Hodin R (2012). Chilaiditi syndrome: a rare

entity with important differential diagnoses. *Gastroenterology & Hepatology*, 8(4), 276–278.

Platz T, Barker M, Carlo J and Lord J (2006). Chilaiditi syndrome--an interesting complication in a bariatric surgery patient. *Surgery for Obesity and Related Diseases : Official Journal of the American Society for Bariatric Surgery*, 2(1), 57–60. <https://doi.org/10.1016/j.soard.2005.10.011>

Suarez-Grau J, Chaves C, Bernal F and Ciuro F (2011). Colonic pseudo-colonic obstruction (Ogilvie syndrome) in a patient with Chilaiditi syndrome. *Cirugia española*, 89(8), e2. <https://doi.org/10.1016/j.ciresp.2010.03.042>

Yagnik V (2010). Chilaiditi sign. *Lung India : Official Organ of Indian Chest Society*, 27(3), 190. <https://doi.org/10.4103/0970-2113.68311>

Yin A, Park G, Garnett G and Balfour J (2012). Chilaiditi syndrome precipitated by colonoscopy: a case report and review of the literature. *Hawai'i Journal of Medicine & Public Health : A Journal of Asia Pacific Medicine & Public Health*, 71(6), 158–162.